

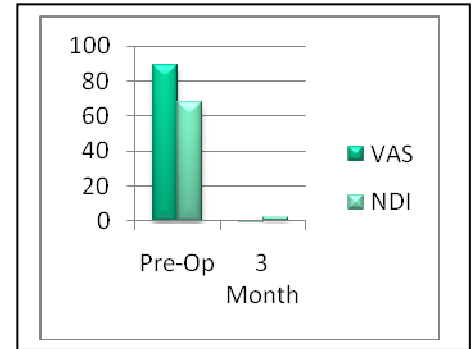
Cindy M. Copper 50 years old

Surgery Date: 05-26-09

Herniated Disc and Annular Tear


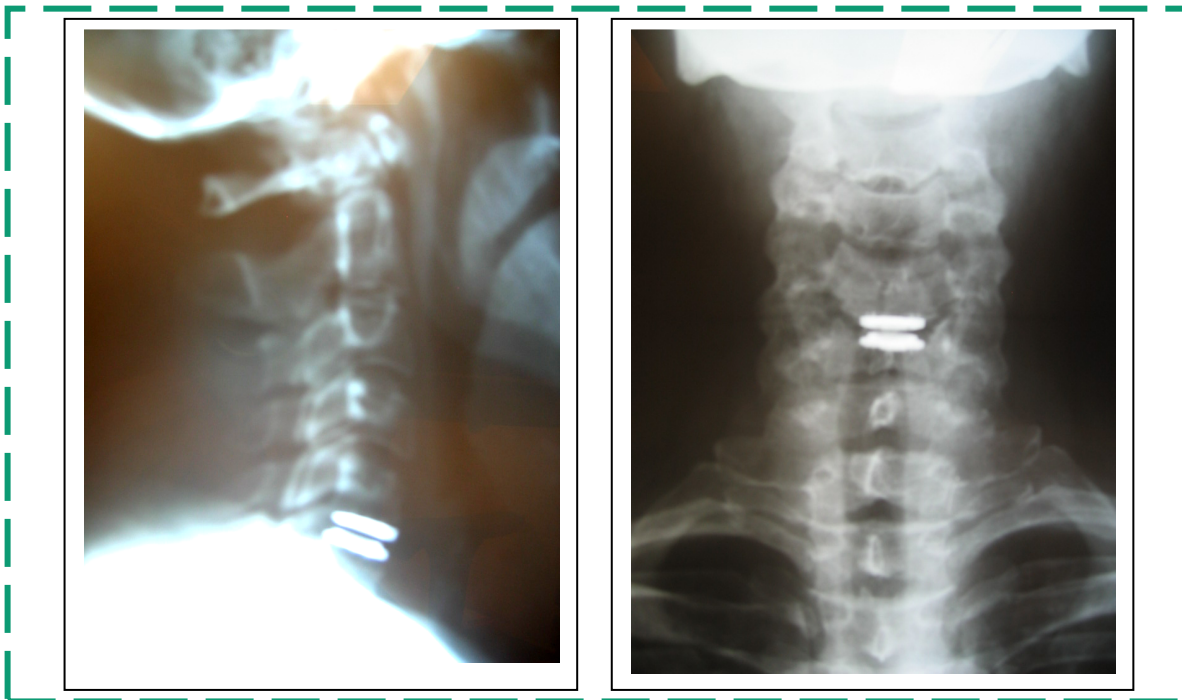
Neck Pain, Headaches,

Intrascapular Pain



“Before surgery I had constant headaches, neck pain that was at a 10+, numbness, tingling and pain down both arms”

Discover Artificial Disc Replacement at C5-6



Cindy is now able to read, concentrate, do any activities she chooses including yard work and sit for any length of time.

“I have no headaches, no neck pain and no arm pain”