

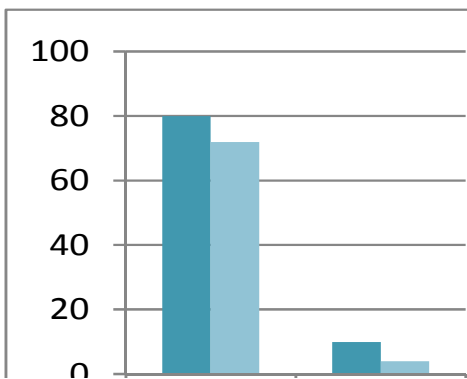
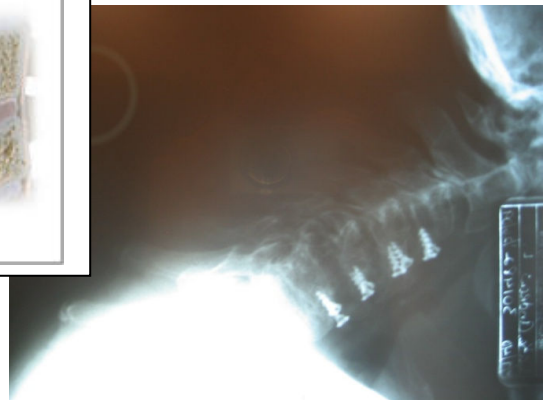
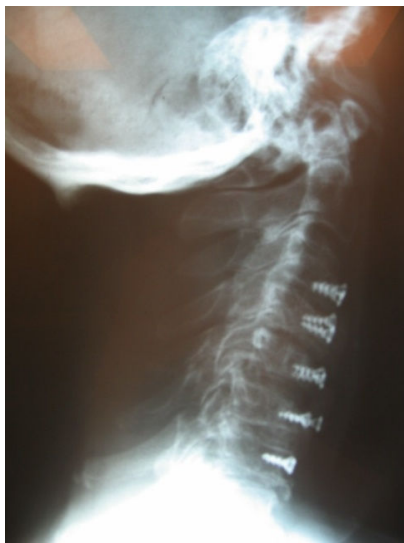**Andrew L. Lake** 69 years old

Surgery Date: 07-29-2008

Impending Myelopathy, Severe Neck Pain,  
Headaches, Interscapular Pain and Progressive  
Radiculopathy

Andy described his pre-op pain as  
*“Constant and Debilitating”*

NeoDisc Artificial Disc Replacement at C3-4,  
C4-5, C5-6 and C6-7



**“I just wished the 69 year old  
body could keep up with the 20  
year old neck”**

Andy is now able to live without pain and  
can participate in *anything* he wants to do.