



Dean A. Kness, D.C.

56 Years Old

Surgery Date: 07-21-2009

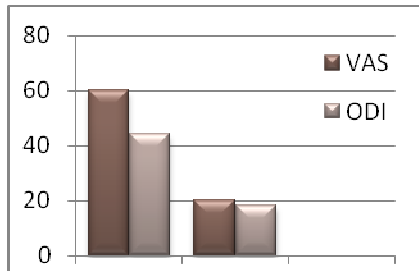
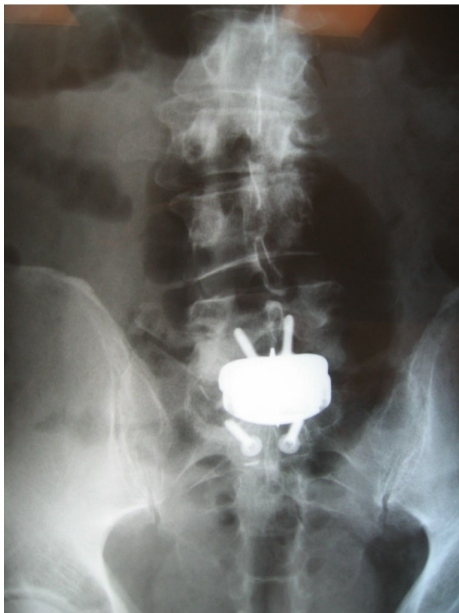Disc Space Collapse, Annular Tear

Stenosis and Discogenic Pain

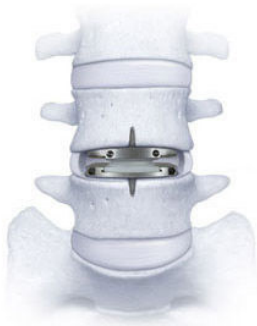
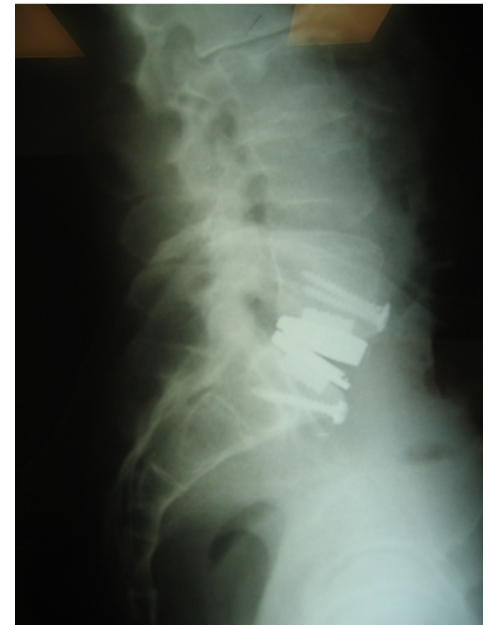

“Constant low back pain,” is how Dean described his symptoms pre-operatively. He was often in the range of a 6-8 on the Visual Analog Scale for Pain. He also experienced left sided sciatica and left foot symptoms that were frequent to constant for the past 2 years.

ProDisc L Artificial Disc Replacement at L5-S1



I am able to stand, sit, and rise from seated position without pain or waiting for back pain and stiffness to diminish before moving



Dean is feeling great with no sciatica symptoms since one day post surgical. He is able to stand erect, where he used to be anteriorly antalgic.

He can now sit, stand, walk, and rise from a sitting position.